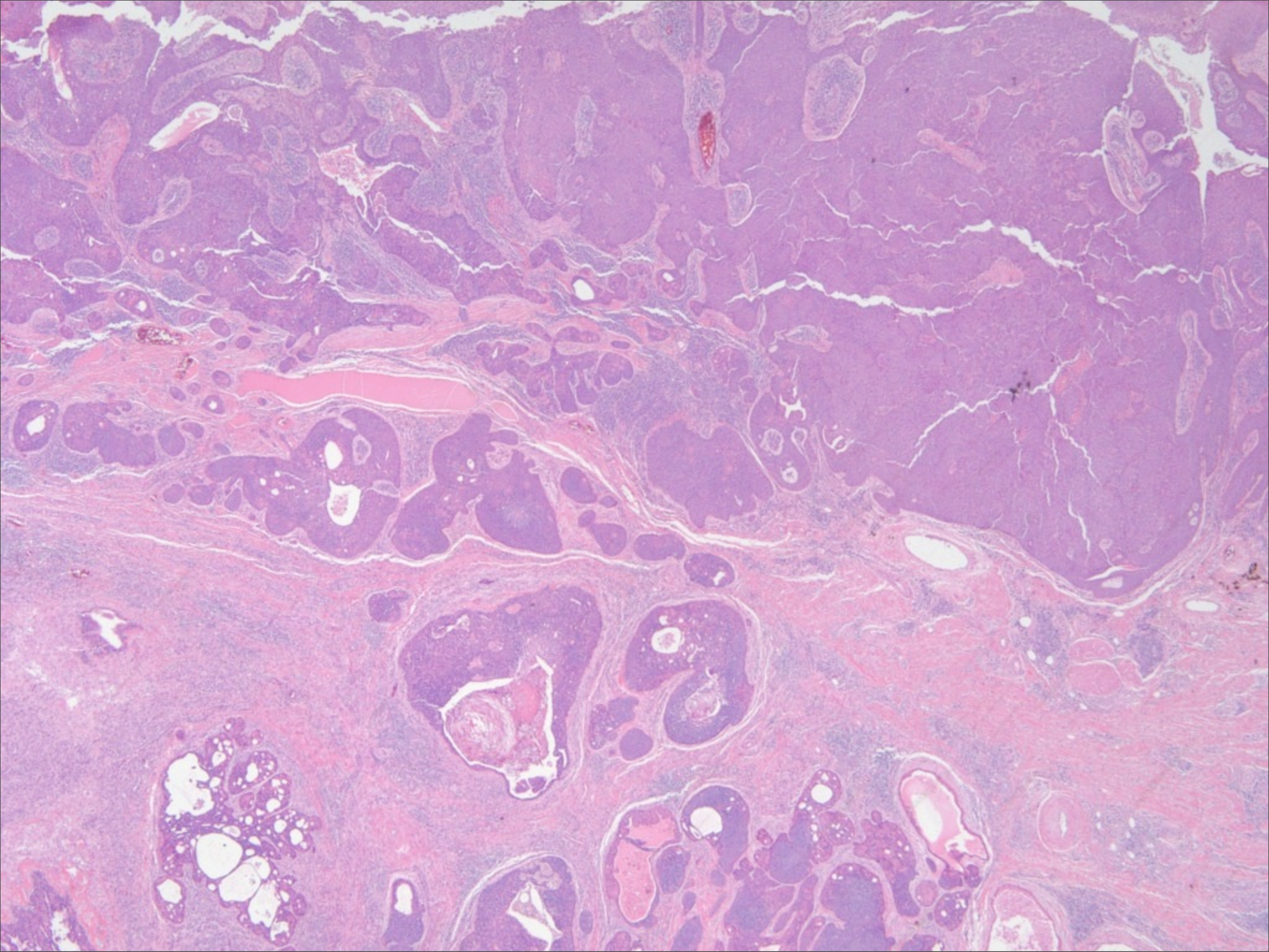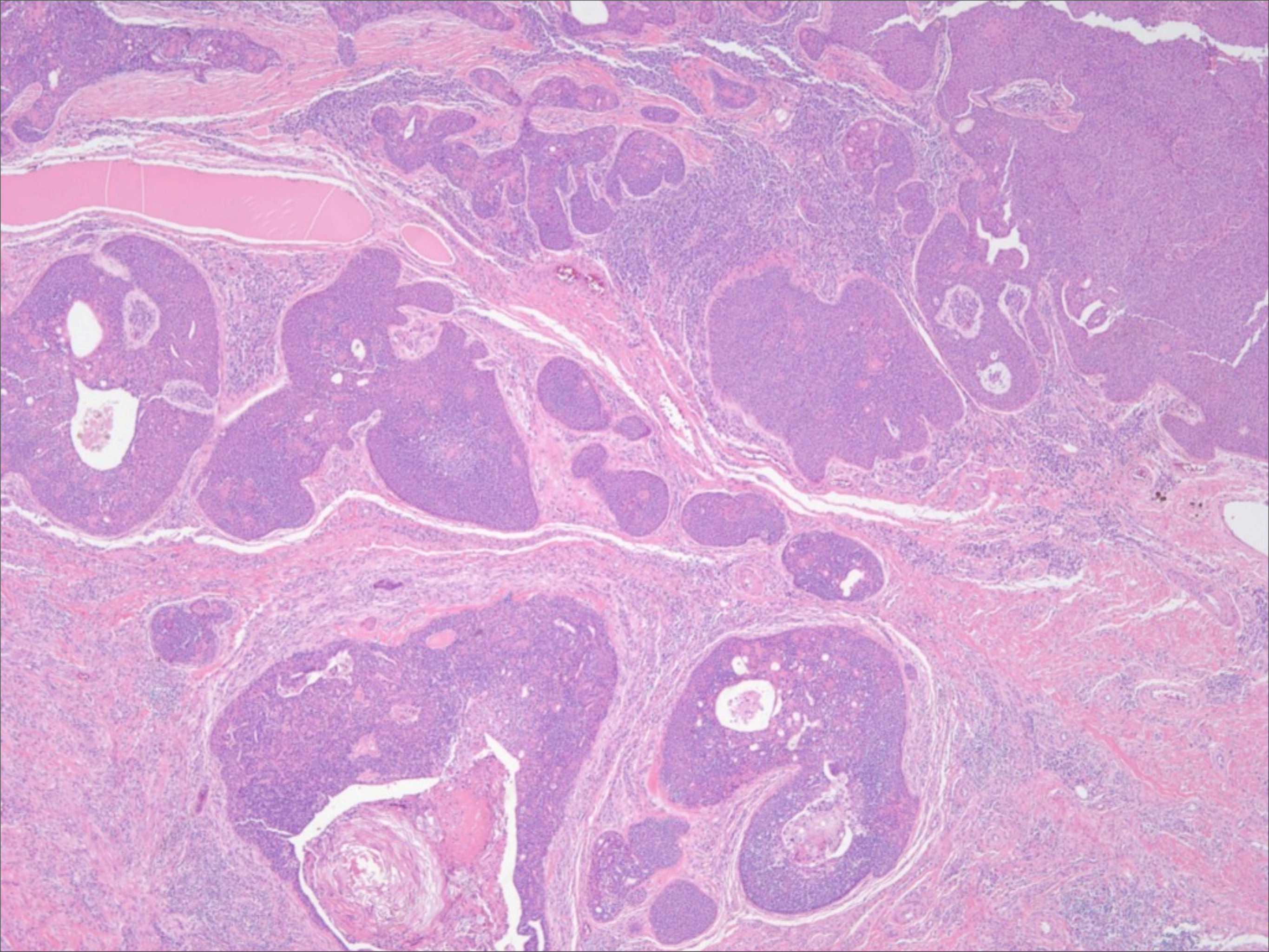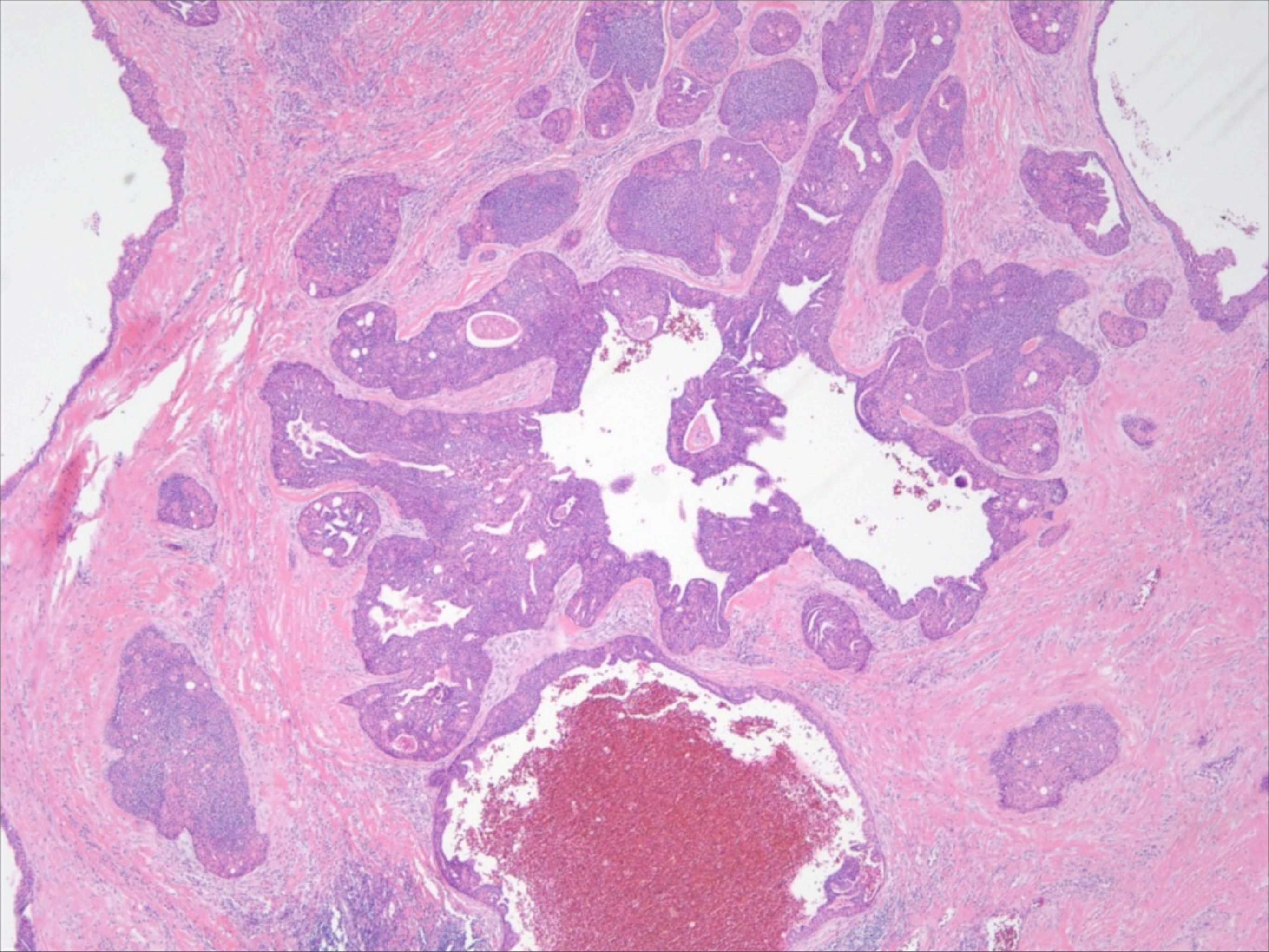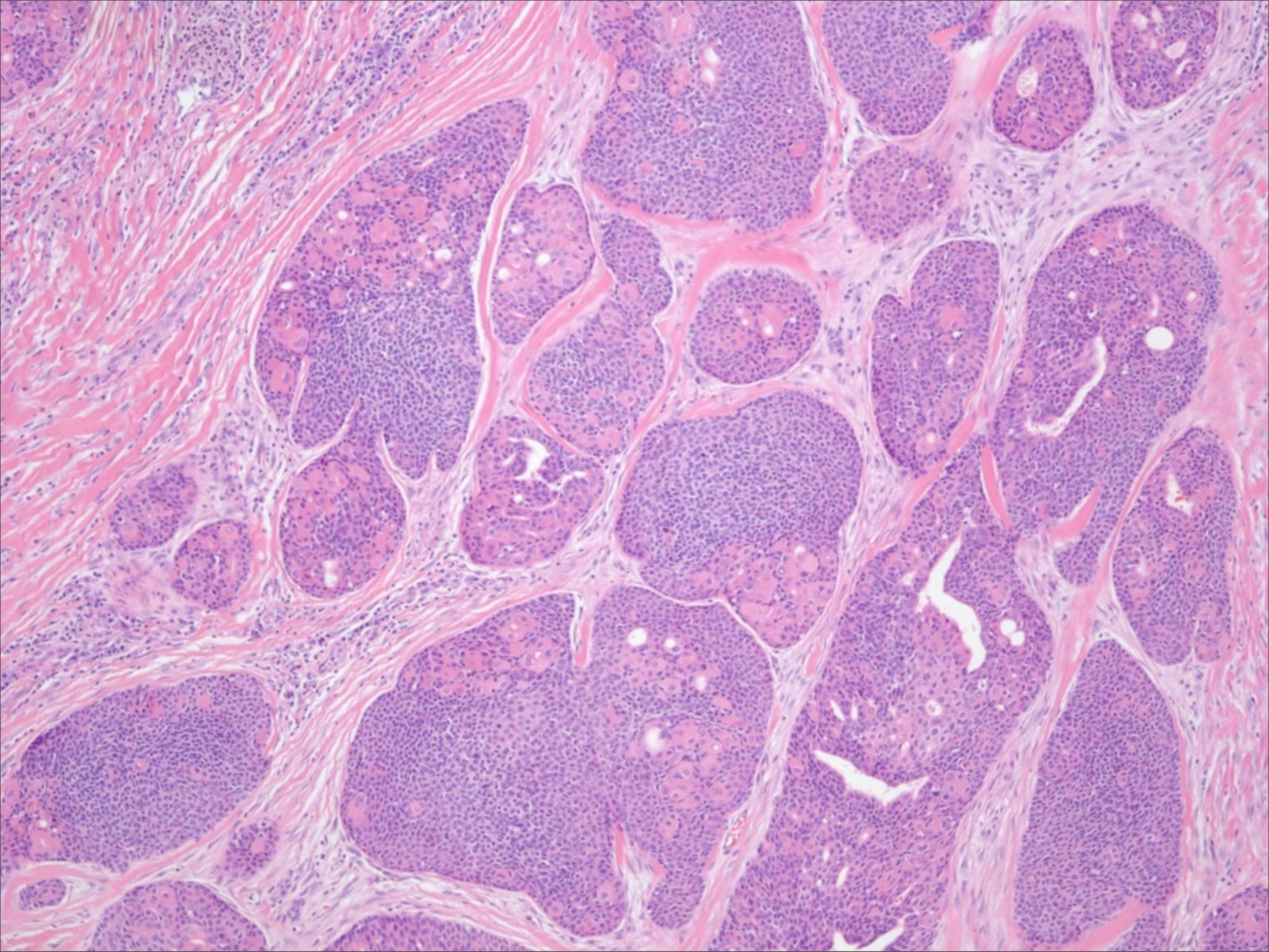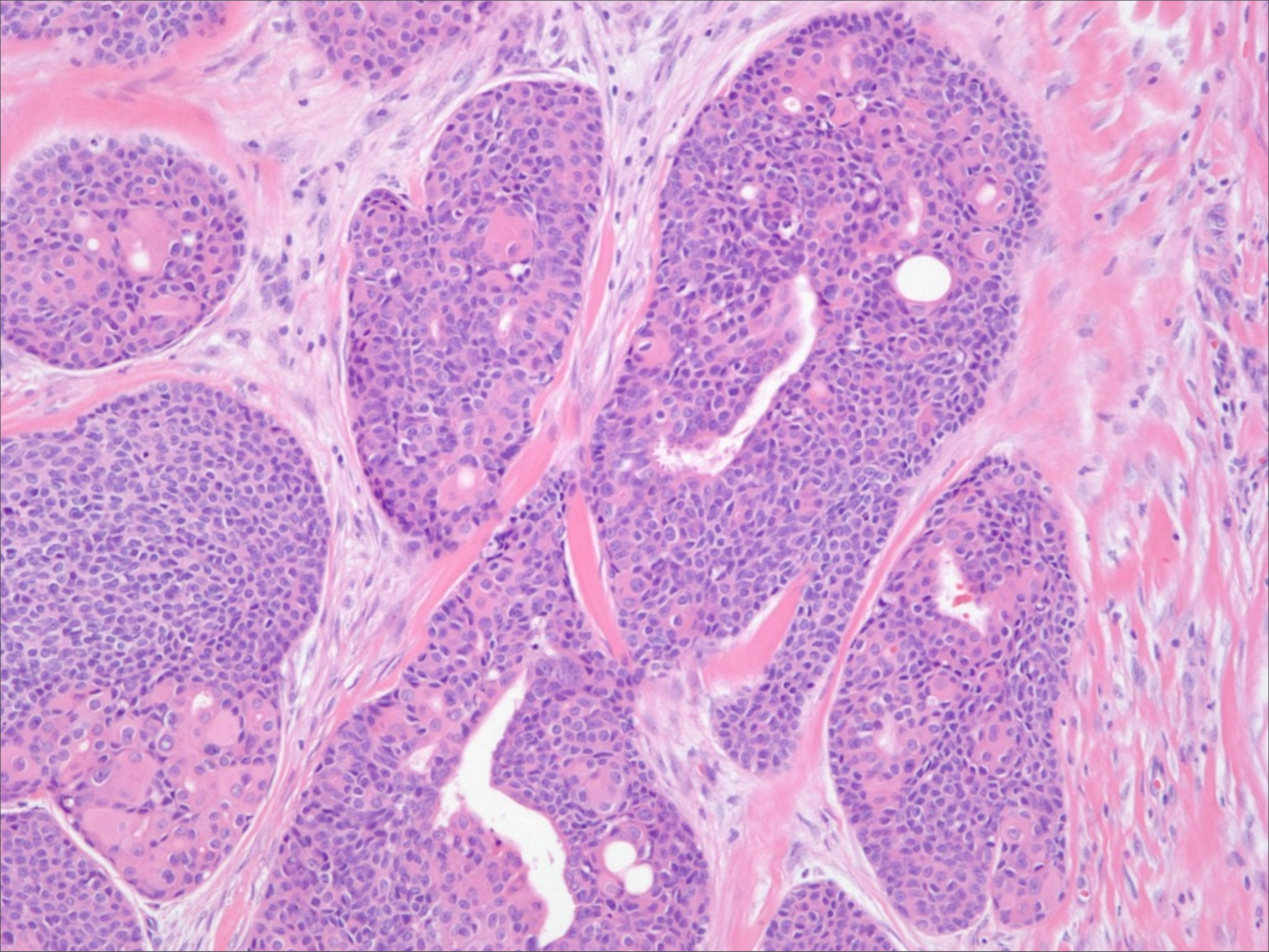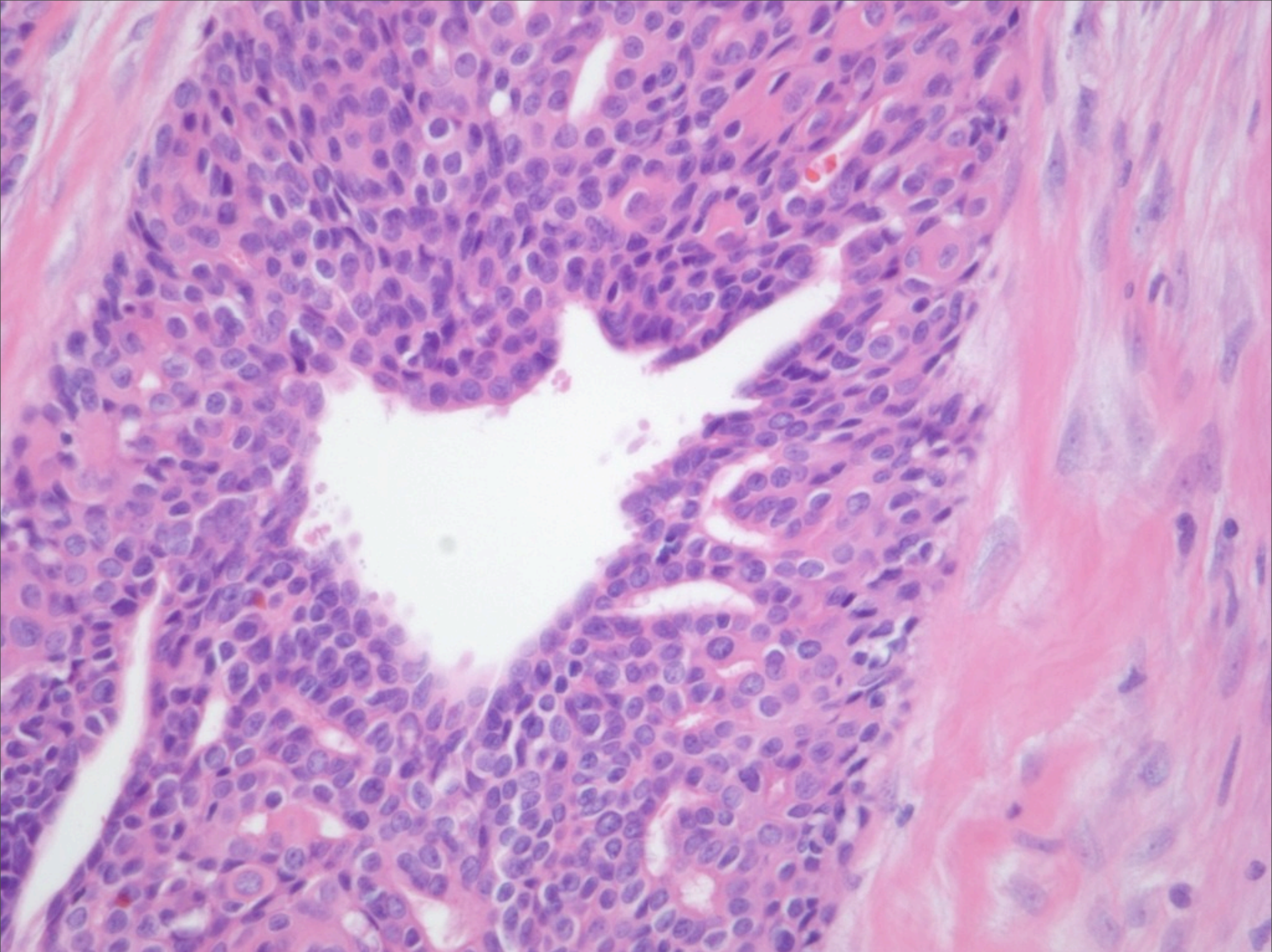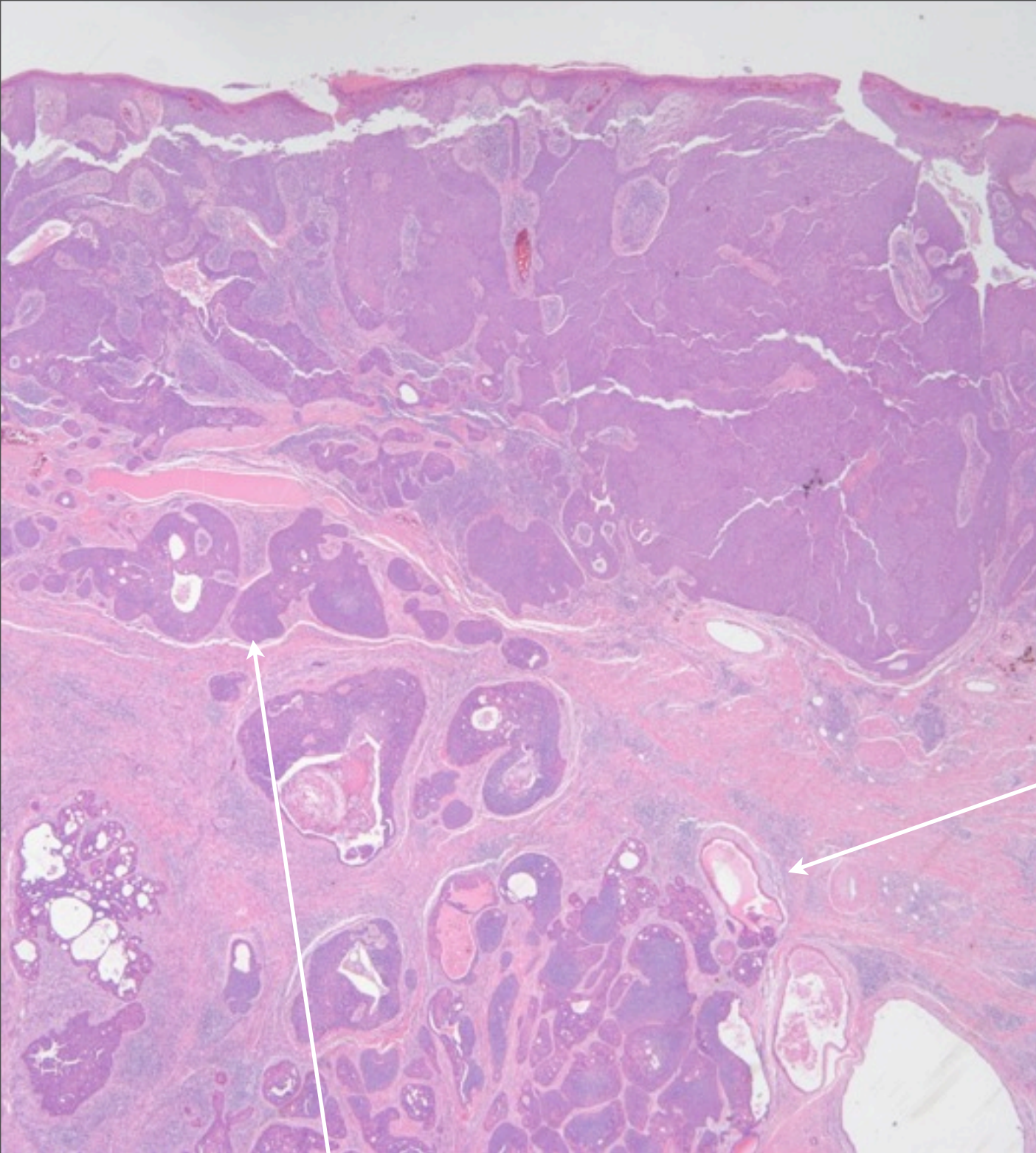




# Hidradenocarcinoma, Low Grade





Squamous cells admixed  
with  
eccrine/apocrine  
ductal epithelium

Cysts with  
Papillary Projections

Platelike growth in  
continuity with invasive ducts